

TITLE PAGE

Title: Fiber Types of the Anterior and Lateral Cervical Muscles in Elderly Males

Type of article: Original article

Authors: Jon Cornwall^{1*}, Ewan Kennedy²

1. Department of Anatomy, University of Otago, Dunedin, New Zealand

2. School of Physiotherapy, University of Otago, Dunedin, New Zealand

***Correspondence to:** Dr Jon Cornwall, Department of Anatomy, University of Otago, PO

Box 913, Dunedin, New Zealand.

Email: jon.cornwall@otago.ac.nz

Phone: +64.3.470.4696

Fax: +64.479.7254

Total figures and tables: 3 tables, 2 figures

Running title: Anterior cervical muscle fiber types

Abstract

Purpose: The anterior and lateral cervical muscles (ALCM) are generally considered to be postural, yet few studies have investigated ALCM fiber types to help clarify the function of these muscles. This study aimed to systematically investigate ALCM fiber types in cadavers.

Methods: Anterior and lateral cervical muscles (4 scalenus anterior, medius, posterior muscles; 5 longus colli, 5 longus capitis taken bilaterally from one cadaver) were removed from four male embalmed cadavers (mean age 87.25 years). Paraffin embedded specimens were sectioned then stained immunohistochemically to identify type I and II skeletal muscle fibers. Proportional fiber type numbers and cross-sectional area (CSA) occupied by fiber types were determined using stereology (random systematic sampling). Results were analyzed using ANOVA ($P < 0.05$) and descriptive statistics.

Results: Scalenus anterior had the greatest average number and CSA of type I fibers (71.9% and 83.7%, respectively); longus capitis had the lowest number (48.5%) and CSA (61.4%). All scalenes muscles had significantly greater type I CSA than longus capitis and longus colli; scalenus anterior and medius had significantly greater type I numbers than longus capitis and longus colli. Some significant differences were observed between individual cadavers in longus colli for CSA, and longus capitis for number.

Conclusion: The ALCM do not share a common functional fiber type distribution, although similar fiber type distributions are shared by longus colli and longus capitis, and by the scalene muscles. Contrary to conventional descriptions, longus colli and longus capitis have type I fiber proportions indicative of postural as well as phasic muscle function.

Key Words: Anterior cervical muscles; lateral cervical muscles; fiber type; muscle function.

INTRODUCTION

Chronic neck pain is stated as having a lifetime prevalence of between 26% and 71%, and reportedly accounts for 15% of hospital physiotherapy visits and up to 30% of chiropractic visits [1]. This is therefore a costly condition for both patients and healthcare systems. The anterior and lateral cervical muscles (ALCM) contribute to movement and stability of the cervical spine and are intimately related to the pathology and effective rehabilitation of cervical spine disorders [2, 3, 4]. These muscles lie anterior to the vertebral column and include longus capitis, longus colli, and the scalenes (anterior, medius, posterior) (Figure 1). Longus colli is attached to the anterior arch of the atlas and vertebral bodies between C2 and C7 and has three parts (superior oblique, inferior oblique, and vertical) of which the oblique portions attach between C3 and C6. The longus capitis is attached more laterally to the anterior tubercles of the transverse processes of C3 to C6 and passes superiorly to attach to the inferior aspect of the basiocciput [5, 6]. The scalene muscles (anterior, medius, posterior) are attached to the cervical transverse processes superiorly (between C2 and C7) and the superior aspect of the first (scalenus anterior and medius) or second (scalenus posterior) rib inferiorly [5, 6]. The ALCM all contribute to flexion of the cervical spine [5, 6], and to a variable extent to lateral flexion and rotation [6] and proprioception [7]. In addition, the scalenes elevate the first and second ribs and are said to be active during inspiration [5, 6].

The ALCM are described as playing an important role in cervical posture [4] and are considered to be involved in a range of pathologies. Studies have indicated that the ALCM are variably affected in whiplash [8], anterocollis [9], headache [10], myotonic dystrophy [11], acute calcific tendonitis [12] and chronic cervical pain [13, 14]. As a consequence of their

involvement in these pathologies, they are often targeted during the treatment and rehabilitation of cervical spine disorders [11, 15].

Few studies have investigated the fiber types of individual ALCM despite the fact that this information could provide guidance on appropriate functional rehabilitation and treatment regimens [16, 17, 18]. Skeletal muscle fibers are commonly classified into either “slow type I” or “fast type II” fibers, according to their relative speed of contraction and distribution of major contractile protein isoforms [19, 20]. Fiber type proportions and their distribution within muscles vary with age, muscle activity, and pathology. Knowledge about the proportion and area occupied by each fiber type therefore has the potential to inform about function, which is therefore relevant to surgical intervention, biomechanical modeling, and rehabilitation regimens [2, 3]. An understanding of fiber types is critical to the development of targeted treatment regimens, as tonic exercises for a primarily phasic muscle (or vice versa) have the potential to exacerbate rather than ameliorate pathologies and delay effective recovery of muscle function. The aim of this study was to quantify fiber type numbers and proportions within and between selected ALCM muscles.

MATERIALS AND METHODS

Anterior cervical muscles (4 scalenus anterior, medius and posterior muscles; 5 longus colli; 5 longus capitis) were removed from four embalmed male cadavers (mean age 87.25 years; range 79 - 95 years, SD 7.93 years) that became available with the majority of these muscles in-tact over an eighteen month period. The longus capitis and longus colli were removed bilaterally from one cadaver; data from these two sides were pooled for the samples acquired from this one cadaver. All human material was obtained in accordance with the New Zealand Human Tissue Act (2008).

Transverse blocks were taken at multiple cervical levels from each muscle based on the vertebral level of origin of each fascicle (Table 1) (Figure 1); these were paraffin embedded and subsequently sectioned (5 μ m). Sections were immunohistochemically stained for type I and II muscle fibers using either antislow (NOQ7.1.1A; 1:100; courtesy of Dr Robin Fitzsimons) or antifast (MY32; 1:200; Sigma, MO) antibodies followed by biotinylated goat anti-mouse IgG secondary antibody (1:200; Amersham PLC, Buckinghamshire, UK). Secondary detection was with the Vectase ABC kit (Elite PK-6100 Standard, Vector Laboratories, CA) and diaminobenzidine (DAB) (D-0426, Sigma-Aldrich Co., St Louis, MO) as the chromogen to detect horseradish peroxidase. Sections were covered with DAB and color monitored by eye for 3 to 5 minutes before dehydrating through a series of graded ethanols followed by xylene before cover slipping, storage and examination by light microscopy (Olympus SZ-ST5 with SZ-40 lens, Olympus Corp., Tokyo, Japan).

Stereology (random systematic sampling) was used to estimate the proportion of fiber type numbers (4% total area counted per section) and proportional cross-sectional area (CSA) occupied by each fiber type across the whole of each section. The figure of 4% provides a higher fiber count than those undertaken in other studies where fiber type proportions have been examined [16, 18, 19]. Proportional number of type I fibers was derived from counting individual fibers present in defined systematically sampled locations, whereas proportional CSA was calculated by identifying the fiber type found on predetermined points in systematically sampled locations. For ease of analysis values were calculated using data on type I fibers (which were the inverse of the proportion and cross-sectional area of type II fibers) (Figure 2). STATA (StataCorp, College Station, TX) statistical software was used to calculate descriptive statistics and analyze data by one-way ANOVA with *post hoc* Sidak test (significance at $P < 0.05$). Analysis included all vertebral levels where more than two samples were available for that particular level. Within muscle analysis included ANOVA assessing the same muscle from each cadaver by individual muscle (e.g. between each longus colli) and cervical level (e.g. between each cervical level for longus colli), and between muscle analysis compared the means of each muscle (e.g. between longus colli and scalenus anterior).

RESULTS

In total 91 sections were processed and analyzed (Tables 1, 2). In total 59,013 fibers were counted (32,794 type I, 26,219 type II), with an average of 648 fibers counted per section. For cross-sectional areas, an average of 528 fibers (384 type I, 143 type II) were counted per section. Scalenus anterior had the greatest average proportional number and CSA of type I fibers (71.9% and 83.7%, respectively), while longus capitis had the lowest proportional number (48.5%) and CSA (61.4%).

Within muscle ANOVA

With the exception of longus colli, where one cadaver was different to two others (cadaver one versus cadavers two and three), there were no significant differences in CSA of type I fibers within individual muscles. For longus capitis, one cadaver showed a significant difference in type I number to one other cadaver (cadaver two versus cadaver four). There was no significant difference between cervical level within any individual muscle.

Between muscles ANOVA

Compared to both longus capitis and longus colli, all scalenes muscles had a significantly greater CSA of type I fibers (Table 3). The scalenes anterior and medius muscles had a significantly greater proportional number of type I fibers than both longus capitis and colli. Scalenus anterior had a significantly greater number, but not CSA, of type I fibers than scalenes posterior.

DISCUSSION

This study reports on fiber types from different ALCM at multiple cervical levels. Only three previous studies have assessed human ALCM fiber types and two of these analyzed muscle samples from patients with cervical pathology [16, 17, 18]. The scalene muscles had a significantly higher proportional cross-sectional area occupied by type I muscle fibers compared to the muscles attaching to the vertebral bodies (longus capitis and longus colli), suggesting functional differences between these two muscle groups. The proportional number of type I fibers was significantly higher in the scalenes anterior and medius muscles compared to longus colli and longus capitis, but not in scalenes posterior. Fiber type proportions were homogeneous throughout individual muscles, indicating samples taken from any region of these muscles may be representative of the proportional fibre type number and CSA throughout the length of the muscle.

On average, the proportional number of type I muscle fibers for the ALCM examined in this study ranged from 48.5% (longus capitis) to 71.9% (scalenus anterior). Muscles that are considered highly tonic, postural muscles have much higher proportions of type I fibers. Thus, type I fibers account for 87.7% in soleus [21] and 89% in the thoracolumbar transversospinal muscles [22]. In contrast, muscles that are more phasic such as biceps femoris and sartorius have fewer type I fibers (66.9% and 49.6%, respectively) [21] and highly phasic muscles such as triceps brachii and orbicularis oculi have even lower proportions (32.6% and 15.4%, respectively) [21]. Our results suggest that the ALCM are not as highly tonic as previously considered, particularly longus colli and longus capitis.

The average proportional number of type I muscle fibers in longus colli in elderly male cadavers in this study (50.0%) is similar to the 52.8% figure reported in young healthy adults [18], but is less than the 62.6% reported in a sample of adults with pre-existing pathology [17]. Sarcopenia is known to develop in human skeletal muscles in the elderly, causing a decrease in the total number of muscle cells, an increase in the proportion of type I muscle fibers, and a decrease in the size and alteration in the shape of the type II muscle fibers [20]. The presence of small and angular type II muscle fibers in our specimens is consistent with age-related sarcopenia and it is therefore surprising that our results were similar to those of Boyd-Clark et al. [18]. Results for the scalene muscles are difficult to compare with those of Sanders et al. [16] as their data included combined measurements from scalenus anterior and scalenus medius. Small but non-significant differences in the proportion of type I muscle fibers were found between these two muscles (71.9% scalenus anterior and 64.0% scalenus medius). However, our small sample size may mask real differences.

Our all male sample precluded any analysis of sex differences in fiber type proportions. Such differences have been described in the lumbar paravertebral muscles: in females, both fiber types are reported to be smaller [23] and the cross-sectional area occupied by type II muscle fibers is also less [24]. Sanders et al. (1990) noted differences between sexes for the scalene muscles, and the two previous studies on longus colli indicated a larger proportion of type I fibers in longus colli in women, with values of 58.3% [18] and 69% [17]. Future studies could assess whether such differences exist between sexes in the muscles included in this study.

This study provides data on both proportional fiber type numbers and CSA in the ALCM of elderly males. Previous studies of cervical muscle function have only recorded fiber type numbers [16, 17, 18], though other studies of spinal muscles have examined proportional CSA occupied by each fiber type [23]. Proportional CSA provides an alternative measure of muscle function to proportional fiber number; the variation between proportional CSA and proportional number observed within individual muscles in this study (e.g scalenus posterior, proportional number 52.3% type I vs proportional CSA 76% type I) suggest comparison of values originating from these two methods may not be valid.

Limitations

This study has some limitations, not least the small sample size and the use of samples from elderly male cadavers. However, the total amount and extent of fiber type sampling in this study was greater than in previous reports on spinal muscles [16, 17, 18, 23, 25] and there are unique data presented on homogeneity of fibre type within muscles. Furthermore, entire muscle sections were selected for stereologic analysis to minimize the risk of using small non-representative areas of the muscle; such errors can occur when assessing muscle biopsies [19]. This factor could explain some of the observed differences between our findings and previous studies on the ALCM where muscle biopsies were assessed [16, 17, 18]. Some anatomical variation was noted during dissection, whereby the length or total excursion of individual muscles along the vertebral column varied. This variation lead to samples from some cervical levels not being available for all cadavers from all cervical levels assessed, however enough samples were gathered to allow statistical analysis to be performed. Lastly, the cadavers used in this study were embalmed with an alcohol-based mix, and tissue shrinkage occurring

secondary to dehydration cannot be excluded though this would not affect the validity of the fiber type counts that were performed in this study. It is unknown whether such fixation may preferentially affect dehydration or the alteration of size in different fiber types, however results still provide valid data for comparison with other studies where similar embalming mixtures are used on donor tissues.

In conclusion, the ALCM of elderly male individuals should not collectively be considered as primarily postural muscles of the cervical spine since the proportional number of type I muscle fibers in longus colli and longus capitis are comparable to other muscles that are commonly thought of as being non-postural and engaged in more phasic activity. In general, the scalene muscles contained a significantly greater proportional number and CSA of type I muscle fibers than longus colli and longus capitis. This may reflect the fact that the scalenes muscles also function to elevate the ribs while the cervical spine is fixed, thereby having an ongoing role in respiration and thus consistently undergoing more tonic, aerobic activity. Treatment and rehabilitation regimens should take into consideration the different function of the individual ALCM muscles so that optimal intervention programs can be implemented in elderly male patient populations [2, 3]. Further investigation is required to establish whether these findings are representative of both female and younger individuals.

ACKNOWLEDGMENT

The authors would like to thank Dr XXXX XXXX, Statistician, for his helpful advice with the statistical analysis.

REFERENCES

1. Benyamin R, Singh V, Parr AT, Conn A, Diwan S, Abdi S (2009) Systematic review of the effectiveness of cervical epidurals in the management of chronic neck pain. *Pain Physician* 12:137-157
2. Ylinen J, Takala E-P, Nykanen M, Hakkinen A, Malkia E, Pohjolainen T, Karppi S-L, Kautiainen H, Airaksinen O (2003) Active neck muscle training in the treatment of chronic neck pain in women. *JAMA* 289:2509-2516
3. Ylinen J (2007) Physical exercises and functional rehabilitation for the management of chronic neck pain. *Eura Medicophys* 43:119-132
4. O'Leary S, Falla D, Elliott JM, Jull G (2009) Muscle dysfunction in cervical spine pain: implications for assessment and management. *J Orthop Sport Phys* 39:324-333
5. Moore K, Dalley AF (2006) *Clinically Oriented Anatomy*. 5th Ed. Baltimore: Lippincott Williams & Wilkins. p 1078
6. Standring S (Ed) (2008) *Gray's Anatomy*. 40th Ed. Edinburgh: Elsevier. p 443
7. Boyd-Clark LC, Briggs CA, Galea MP (2002) Muscle spindle distribution, morphology, and density in longus colli and multifidus muscles of the cervical spine. *Spine* 27:694-701
8. Elliott JM, O'Leary S, Sterling M, Hendrikz J, Pedler A, Jull G (2010) Magnetic resonance imaging findings of fatty infiltrate in the cervical flexors in chronic whiplash. *Spine* 35:948-954
9. Flowers JM, Hicklin LA, Marion M-H (2011) Anterior and posterior sagittal shift in cervical dystonia: A clinical and electromyographic study, including a new EMG approach of the longus colli muscle. *Movement Disord* 26:2409-2414

10. Jull G, Barrett C, Ho P (1999) Further clinical clarification of the muscle dysfunction in cervical headache. *Cephalalgia* 19:179-185
11. Nitz JC, Burns YR, Jackson RV (1995) Development of a reliable test of (neck) muscle strength and range in myotonic dystrophy subjects. *Physiother Theory Pract* 11:239-244
12. Wolzak H, van de Rest M, Geurts M, ter Borg E-J (2010) Acute calcific tendinitis of the longus colli muscle. *Clin Radiol* 16:240
13. O'Leary S, Falla D, Jull G. 2003. Recent advances in therapeutic exercise for the neck: Implications for patients with head and neck pain. *Aust Endod J* 29:138-142.
14. Falla D, O'Leary S, Farina D, Jull G (2011) Association between intensity of pain and impairment in onset and activation of the deep cervical flexors in patients with persistent neck pain. *Clin J Pain* 27:309-314
15. Falla D, O'Leary S, Fagan A, Jull G (2007) Recruitment of the deep cervical flexor muscles during a postural-correction exercise performed in sitting. *Manual Ther* 12:139-143
16. Sanders RJ, Ratzin-Jackson CG, Banchemo N, Pearce WH (1990) Scalene muscle abnormalities in traumatic thoracic outlet syndrome. *Am J Surg* 159:231-236
17. Uhlig Y, Weber BR, Grob D, Muntener M (1995) Fiber composition and fiber transformations in neck muscles of patients with dysfunction of the cervical spine. *J Orthopaed Res* 13:240-249
18. Boyd-Clark LC, Briggs CA, Galea MP (2001) Comparative histochemical composition of muscle fibres in a pre- and a postvertebral muscle of the cervical spine. *J Anat* 199:709-716
19. Lexell J, Taylor C, Sjostrom M (1985) Analysis of sampling errors in biopsy techniques using data from whole muscle cross sections. *J Appl Physiol* 59:1228-1235

20. Sheard PW, Anderson RD (2011) Age-related loss of muscle fibres is highly variable amongst mouse skeletal muscles. *Biogerontology* 13:157–167
21. Johnson MA, Polgar J, Weightman D, Appleton D (1973) Data on the distribution of fibre types in thirty-six human muscles: An autopsy study. *J Neurol Sci* 18:111-129
22. Cornwall J, Stringer MD, Duxson M (2011) Functional morphology of the thoracolumbar transversospinal muscles. *Spine* 16:E1053-E1061
23. Mannion AF, Dumas GA, Cooper RG, Espinosa FJ, Faris MW, Stevenson JM (1997) Muscle fibre size and type distribution in thoracic and lumbar regions of erector spinae in healthy subjects without low back pain: normal values and sex differences. *J Anat* 190:503-513
24. Weber BR, Grob D, Dvorak J, Muntener M (1997) Posterior surgical approach to the lumbar spine and its effect on the multifidus muscle. *Spine* 22:1765-1772
25. Rantanen J, Rissanen A, Kalimo H (1994) Lumbar muscle fiber size and type distribution in normal subjects. *Eur Spine J* 3:331-335

LEGENDS

Table 1. Descriptive data indicating proportional number of, and cross-sectional area occupied by, type I muscle fibers within individual anterior cervical muscles. SD - standard deviation; C - cervical; SB - superior belly

Muscle	Levels sampled	No. of samples	Proportional number of type I fibers (%)		Proportional area occupied by type I fibers (%)	
			Mean	SD	Mean	SD
Scalenus anterior	C4,5,6,7	12	71.9	15.0	83.7	6.0
Scalenus medius	C1,2,3,4,5,6,7	26	64.0	13.7	79.7	10.2
Scalenus posterior	C2,3,4,5,6	11	52.3	13.6	76.0	8.48
Longus capitis	C3,4,5,6,SB	20	48.5	11.0	61.4	9.1
Longus colli	C1,3,6	12	50.0	11.1	64.1	8.0

Table 2. Descriptive data indicating proportional number of, and cross-sectional area occupied by, type I muscle fibers within individual anterior cervical levels. Area - Proportional CSA area occupied by type I fibers (%). Prop. - proportional number of type I fibers (%). SB - superior belly

	Longus capitis		Longus colli		Scalenus anterior		Scalenus medius		Scalenus posterior	
	Area	Prop.	Area	Prop.	Area	Prop.	Area	Prop.	Area	Prop.
C1							74.2	52.9		
C2							68.2	52.5		
C3	56.2	49.1	62.2	46.7			82.3	64.2		
C4	64.0	50.7			88.1	79.5	75.9	62.2	78.2	59.8
C5	63.6	48.4			87.1	79.4	86.2	72.5	73.3	51.1
C6	59.2	41.5	65.6	54.9	80.0	64.3	86.2	69.4		
C7							81.1	69.0		
T1			64.5	48.2						
SB	64.3	52.8								

Table 3. Significant difference between individual muscles' for proportion of, and cross-sectional area occupied by, type I muscle fibers. Significant difference indicated by numerals. Where box is divided in two, top half represents significant difference in proportional cross-sectional area occupied by type I fibers, bottom half represents significant difference in the proportional number of type I fibers. NS - not significant.

	Longus capitis	Longus colli	Scalenus anterior	Scalenus medius
Longus colli	NS	NS	NS	NS
Scalenus anterior	<0.001	<0.001	NS	NS
	<0.001	<0.001		
Scalenus medius	<0.001	<0.001	NS	NS
	0.002	0.033		
Scalenus posterior	0.002	0.028	NS	NS
	NS	NS	0.026	

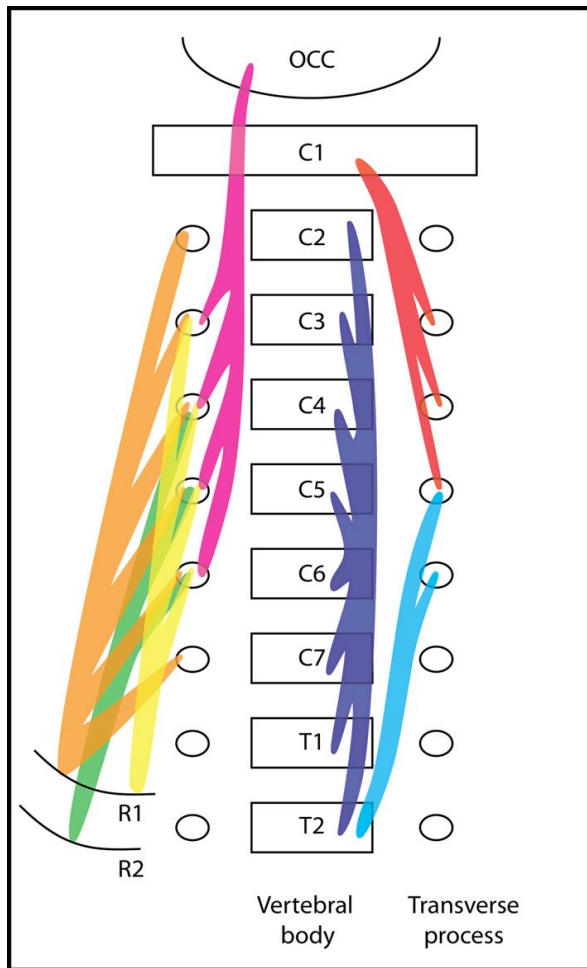


Figure 1. Schematic diagram of the anterior cervical muscles examined. Muscles are shown highlighted in different colors on the anterior aspect of the cervical spine. Legend: Pink - Longus capitis; Purple - vertical component of longus colli; Red - Superior oblique component of longus colli; Light blue - Inferior oblique component of longus colli; Yellow - Scalenus anterior; Orange - Scalenus medius; Green - Scalenus posterior; OCC - occiput; C1 - first cervical vertebra; R1, R2 - ribs one and two




Figure 2. Photomicrograph of processed muscle section from longus colli (C5) identifying type II muscle fibers. Image captured at x40 magnification after immunohistochemistry to identify type II fibers; type II fibers are stained dark, type I fibers appear light.